

# Classification of Diabetic Retinopathy

## I. Nonproliferative (background) retinopathy

- A. Simple background retinopathy
- B. Dot and blot hemorrhages
- C. Hard exudates
- D. Microaneurysms
- E. Macular edema

## II. Preproliferative retinopathy

- A. Soft exudates
- B. Intraretinal microvascular abnormalities (IRMA)

## III. Proliferative retinopathy

- A. Neovascularization of the disc
- B. Neovascularization elsewhere in the retina
- C. Fibrovascular proliferation
- D. Vitreous hemorrhage

LINGID

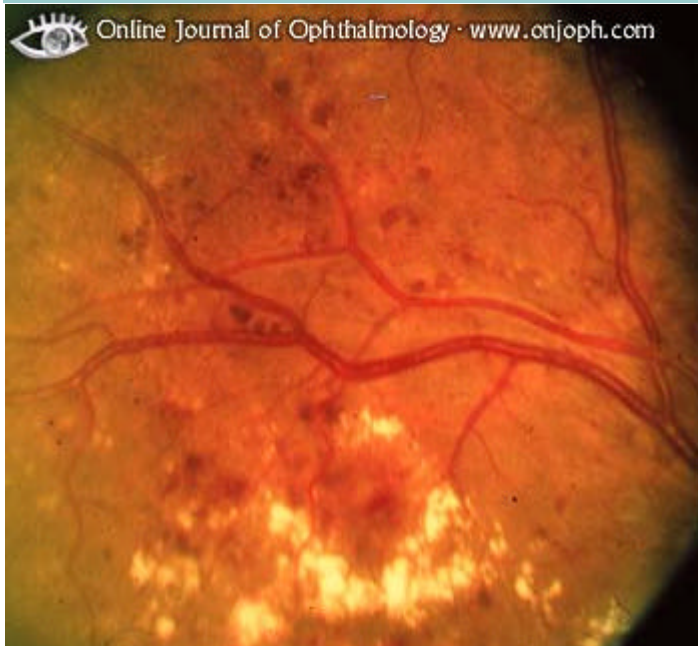<http://www.atlasophthalmology.com/bin/atlas?lang=en>

<http://www.atlasophthalmology.com/bin/atlas?id=115343470-5542565&nav=1720&debug=>

Diagnosis: Diabetic Retinopathy, Nonproliferative (#1,1)

Comment: Many red dots, microaneurysms, are seen together with hard exudate in a circinate pattern.

Image ID: 1949

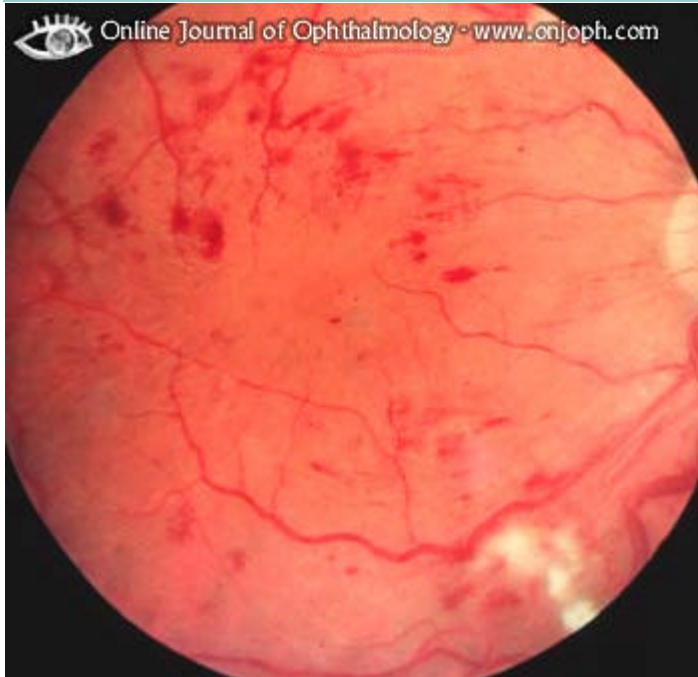

Diagnosis: Diabetic Retinopathy, Nonproliferative (#2)

Comment: Many superficial, intraretinal hemorrhages. The fluffy, white spots, cotton wool spots, are microinfarcts.

Keywords: retina

Image ID: 1947



Diagnosis: Diabetic Retinopathy (#1,1), Proliferative (PDR)

Comment: One has to look carefully to see the heavy neovascularization that extends along the posterior surface of vitreous which is adherent to the disc but detached elsewhere.

Keywords: retina

Image ID: 2008




---

Diagnosis: Diabetic Retinopathy (#3), Proliferative, (PDR)

Comment: Severe macular edema with hard exudates. Neovascularization above the disc.

Image ID: 1946




ICD10-Code: H36.032

Diagnosis: Diabetic Retinopathy (#4), Proliferative (PDR)

Comment: Massive neovascularization along the retinal surface (this indicates that the vitreous is not detached).


Image ID: 1945



Diagnosis: Diabetic Retinopathy (#5), Proliferative (PDR)

Comment: Preretinal hemorrhages occur after traction on new vessels. They can be suspected to be located at the proliferation of the 6 o'clock vein and at 7 o'clock. The hemorrhagic streaks toward the macula indicate a subhyaloid connection to this area.

Image ID: 1944




---

Diagnosis: Diabetic Retinopathy (#6), Proliferative (PDR)

Comment: Proliferations typically occur at the disc and along the arcades. Despite photocoagulation there is still active neovascularization. The vitreous is not detached as indicated by the preretinal location of the neovascularization.

Keywords: retina

Image ID: 1943

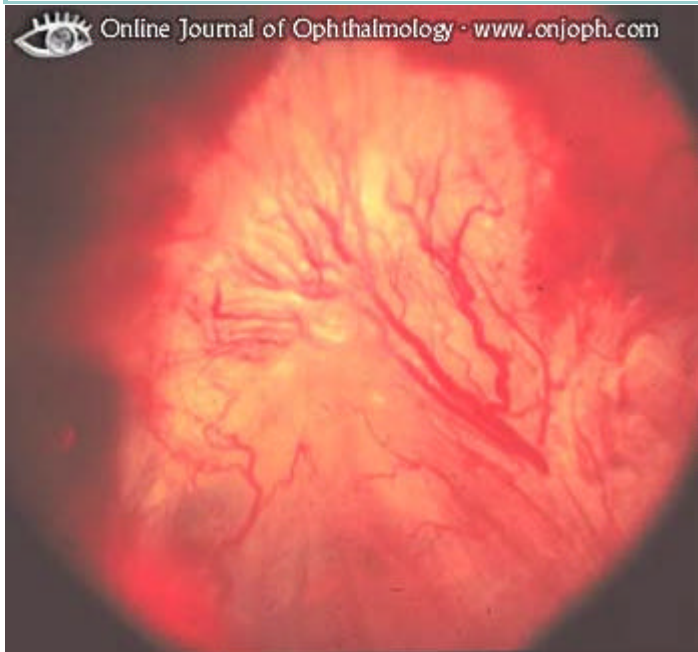

Diagnosis: Diabetic Retinopathy (#9), Proliferative (PDR)

Comment: Severe neovascularization with hemorrhage and proliferation that has detached the retina.

Keywords: retina

Image ID: 2004

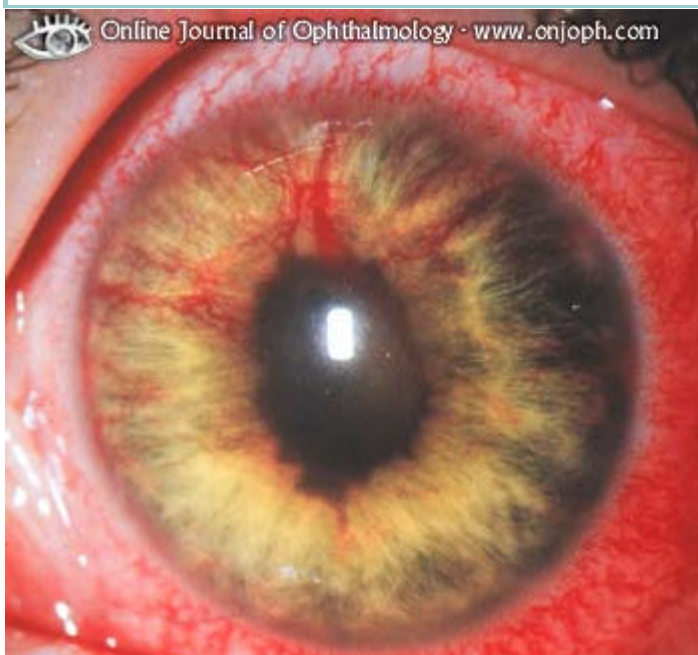

Diagnosis: Diabetic Retinopathy (#8), Proliferative (PDR)

Comment: Neovascularization of the iris, iris bombée, occurring in eyes with active diabetic proliferative retinopathy.

Keywords: retina

Image ID: 2003



# HÜPERTENSIOON JA ARTERIOLOSKLEROOS

PILDID ON KOPEERITUD LINGILT:

<http://www.atlasophthalmology.com/bin/atlas?id=115343470-5542565&nav=1712&debug=>

HÜPERTENSIOONIPUHUSED MUUTUSED SILMAPÕHJADES ( Sulev Maramaa "Areteriaalne hüpertensioon" Tartu 1995

I STAADIUM. Võrkkesta arterid on veenidega võrreled tunduvalt kitsamad, veidi kollakad. Veenid on arteritega ristumise kohtades kokku surutud ( Saluse tunnus).

Väikesed veenid on korgitõmbaja taoliselt looklevad

II STAADIUM. Arterid on veelgi enam ahenenud, meenutavad vasktraati. On üksikuid väikesi valkjaid rasvdegeneratsiooni koldeid ja väikesi verdumisi.

III STAADIUM. Arterid on tugevasti ahenenud, läikivad, valkjaskollased, esineb ristumisfenomen, papill on häperreemiline, kontuurid osalt ebaselged, retinal pilvetaolisi valkjaid alasid ja väikesi verdumisi.

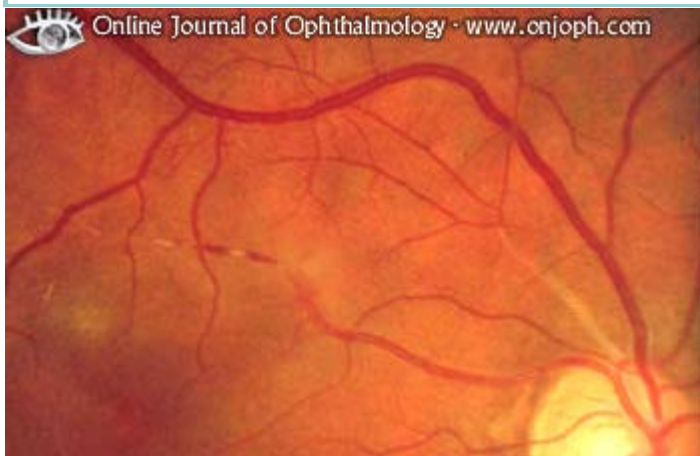IV STAADIUM. Arterid on kitsad, valkjad (hõbetaarterid) ; veenid on laienenud, ristumisfenomen väljendunud, kollatähni umber on tähekujuliselt paigutunud väikesekoldelised eksudaadid, retinal on ebaterava piiriga vatisarnaseid koldeid, verevalumeid. Niisuguse seisundi kõige iseloomulikumaks tunnuseks on paispapill.

Diagnosis: Arteriosclerosis (#1), of Retinal Vessels

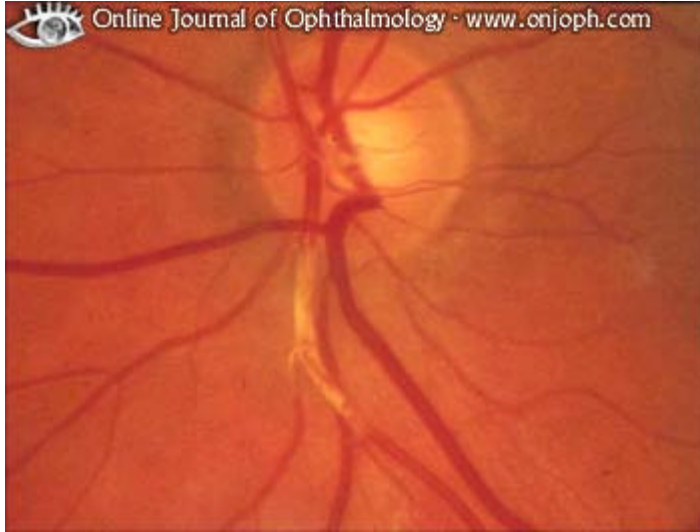Comment: Sclerosis of arterial vessels is shown with thickening of the wall and disappearing visibility of the blood column. Veins appear dilated, and there is edema of the macular area

Keywords: retina

Image ID: 3020



Diagnosis: Arteriosclerosis (#2), of Retinal Vessels  
Comment: Opaque and thickened wall of arterial vessel  
Keywords: retina  
Image ID: 3019

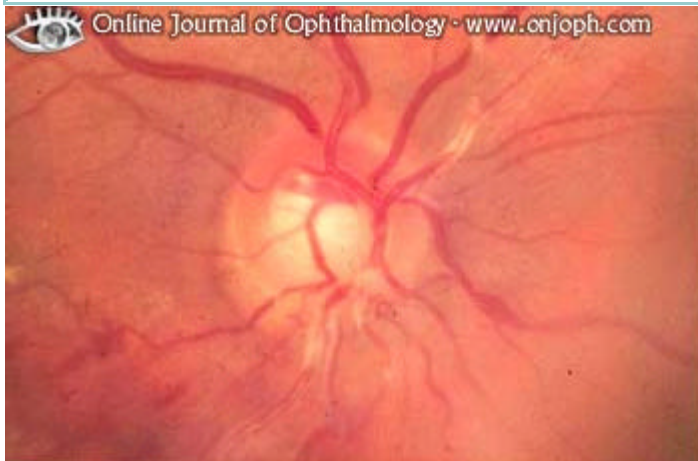

Diagnosis: Arteriosclerosis (#3), of Retinal Vessels

Comment: Ensheathed arterial vessels are seen near the disc. Other signs of hypertension are small intraretinal hemorrhages, some exudates, slight edema of the inferior disc margin, and congested veins.

Keywords: retina

Image ID: 3004

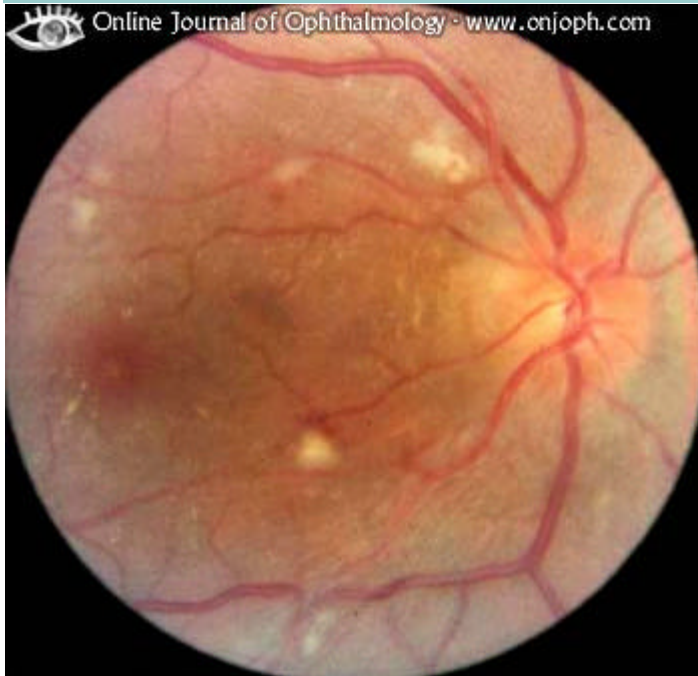

Diagnosis: Hypertensive Retinopathy (#1,1), Cotton-Wool Spot

Comment: The caliber of the veins is increased in relation to the arteries. Several cotton-wool spots are seen and a little bit of exudate.

Keywords: retina

Image ID: 2959





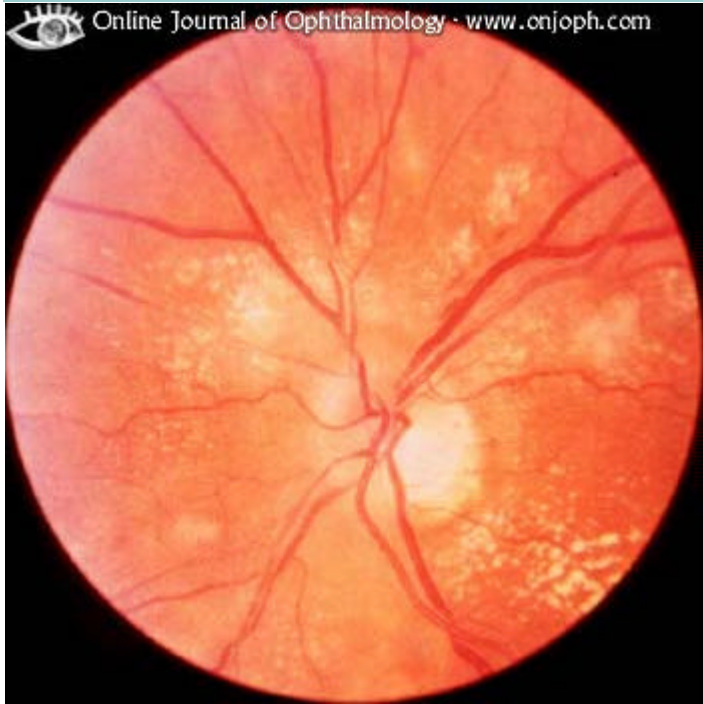---

Diagnosis: Hypertensive Retinopathy (#2,1)

Comment: Thinned straight arteries, increased caliber of the veins, small intraretinal hemorrhages, exudates

Keywords: retina

Image ID: 2961

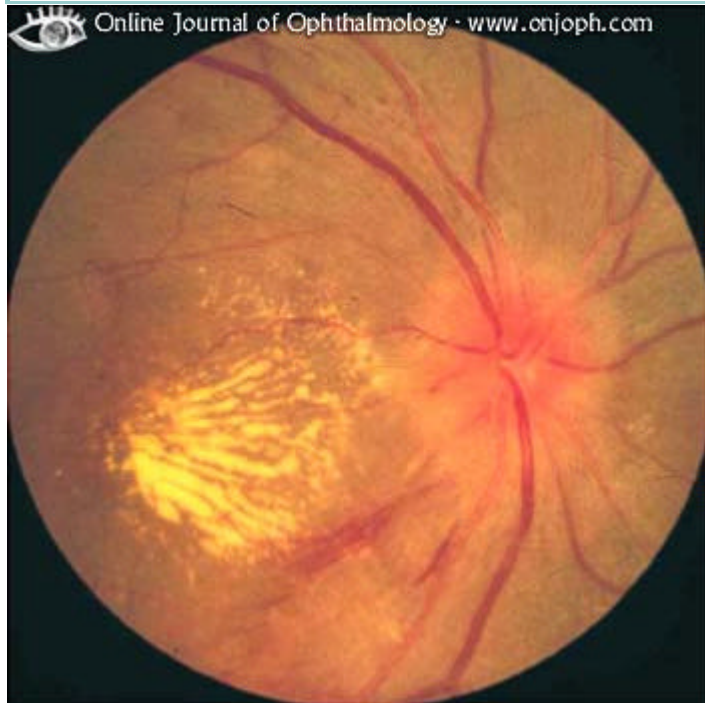

Diagnosis: Hypertensive Retinopathy (#2,2)

Comment: Additional features of hypertension are a blurred disc and exudates in the macula (star shaped)

Keywords: retina

Image ID: 2960



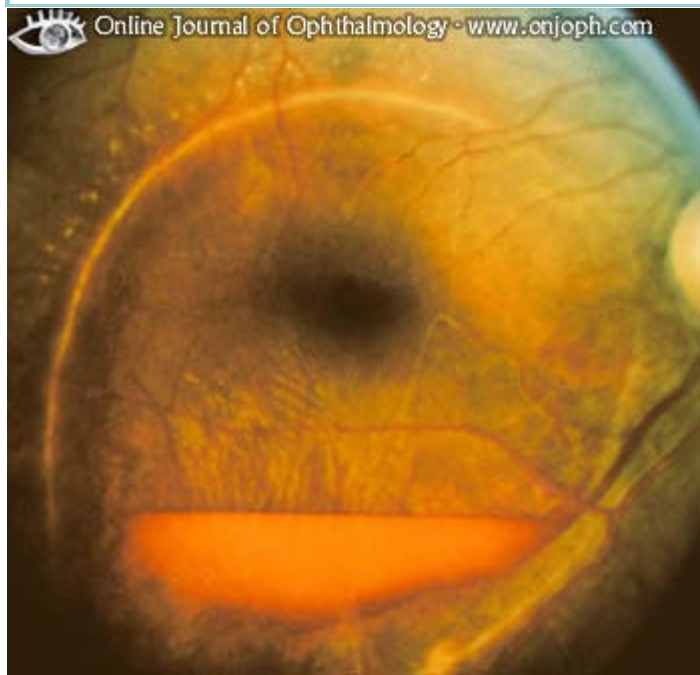ICD10-  
Code: H36.824

Diagnosis: Hypertensive Retinopathy, Intra Retinal Hemorrhage (#3,2)

Comment: Same patient in upright position. The blood is disappearing, the vitreous remains clear. The still detached internal limiting lamina shows fine folds.

Keywords: retina

Image ID: 3809



ICD10-  
Code: H36.824

Diagnosis: Hypertensive Retinopathy, Intraretinal Hemorrhage (#1,1)

Comment: Centrally there is a well-defined accumulation of blood under detached internal limiting lamina. A second ring of blood has less well-defined borders and represents preretinal blood where the vitreous is detached from the retina.

Keywords: retina

Image ID: 2855

